

MODULE 3 L04

Heart Orientation

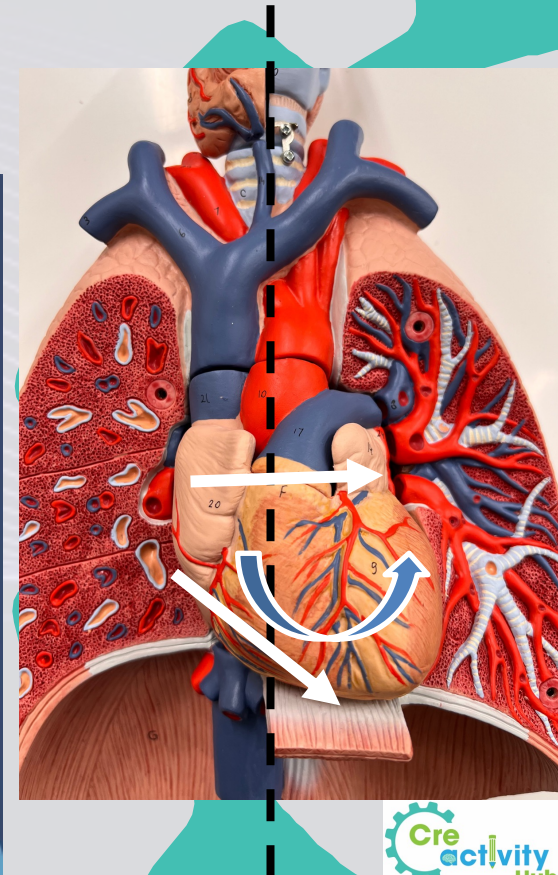
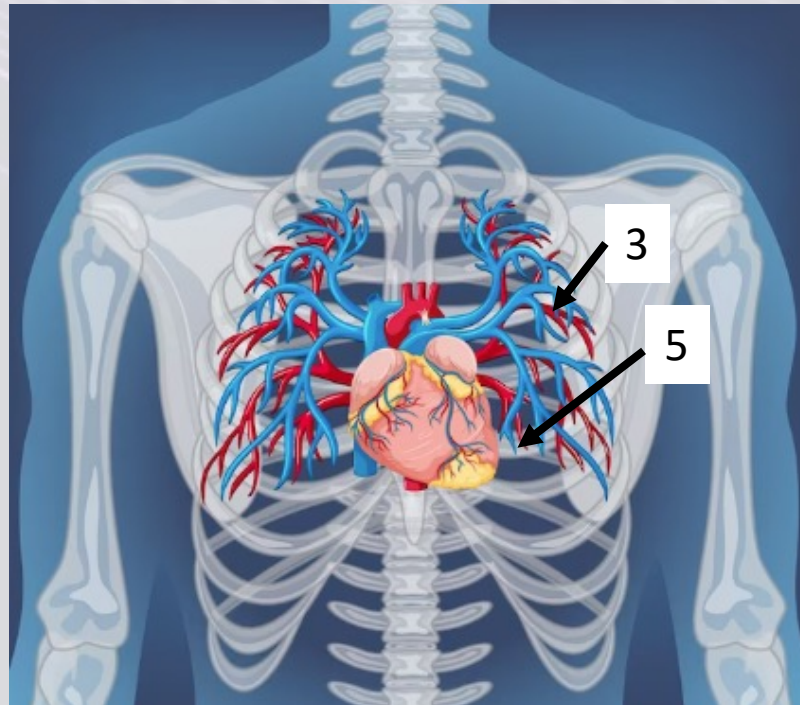
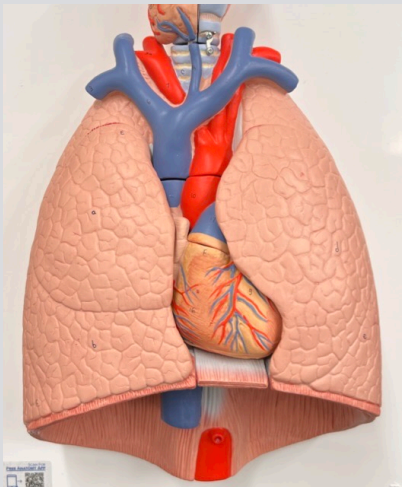
Dr. Lisa Brinn

lbrinn@fiu.edu



4. Heart Orientation

- Midsagittal section
 - ❖ Separates the heart unevenly
 - Due to:
 1. Heart lies slightly to the left
 2. Sits at an angle to the longitudinal axis of the body
 3. Rotated toward the left side
 - right side is more visible
- Located:
 - ❖ Within the mediastinum
 - ❖ Between both lungs
 - ❖ Between ribs 3 and 5



Heart Borders

- Superior border
 - ❖ Base of the heart
 - Contains major blood vessels
 - Superior surfaces of atria
 - Level of rib #3
- Inferior border
 - ❖ Apex of the heart
 - Right ventricle
- Left border
 - ❖ Left atrium
 - ❖ Left ventricle
- Right border
 - ❖ Right atrium

